

blood

Prepublished online April 22, 2013;
doi:10.1182/blood-2012-09-311381

Thrombosis in paroxysmal nocturnal hemoglobinuria

Anita Hill, Richard Kelly and Peter Hillmen

Information about reproducing this article in parts or in its entirety may be found online at:
http://bloodjournal.hematologylibrary.org/site/misc/rights.xhtml#repub_requests

Information about ordering reprints may be found online at:
<http://bloodjournal.hematologylibrary.org/site/misc/rights.xhtml#reprints>

Information about subscriptions and ASH membership may be found online at:
<http://bloodjournal.hematologylibrary.org/site/subscriptions/index.xhtml>

Advance online articles have been peer reviewed and accepted for publication but have not yet appeared in the paper journal (edited, typeset versions may be posted when available prior to final publication). Advance online articles are citable and establish publication priority; they are indexed by PubMed from initial publication. Citations to Advance online articles must include the digital object identifier (DOIs) and date of initial publication.

Blood (print ISSN 0006-4971, online ISSN 1528-0020), is published weekly by the American Society of Hematology, 2021 L St, NW, Suite 900, Washington DC 20036.
[Copyright 2011 by The American Society of Hematology; all rights reserved.](#)



Review: Thrombosis in Paroxysmal Nocturnal Hemoglobinuria

Anita Hill, Richard Kelly and Peter Hillmen

Department of Haematology, St. James's University Hospital, Leeds, UK

Corresponding Author:

Dr Anita Hill

Department of Haematology

Level 3, Bexley Wing

St. James's University Hospital

Leeds

U.K.

Tel: +44 113 2068513

Fax: +44 113 2068177

Email: anitahill@nhs.net

Abstract

The most frequent and feared complication of paroxysmal nocturnal hemoglobinuria (PNH) is thrombosis. Recent research has demonstrated that the complement and coagulation systems are closely integrated with each influencing the activity of the other to the extent that thrombin itself has recently been shown to activate the alternative pathway of complement. This may explain some of the complexity of the thrombosis in PNH. In this review the recent changes in our understanding of the pathophysiology of thrombosis in PNH as well as the treatment of thrombosis will be discussed. Mechanisms explored include platelet activation, toxicity of free hemoglobin, nitric oxide depletion, absence of other GPI-linked proteins such as urokinase-type plasminogen activator receptor and endothelial dysfunction. Complement inhibition with eculizumab generally has a dramatic effect in PNH and has a major impact in the prevention of thrombosis as well as its management in this disease.

Introduction

“We can safely say that PNH is the most vicious acquired thrombophilic state known in medicine”.¹ This statement by Luzzatto reflects the fear of the complication of thrombosis by both patients with paroxysmal nocturnal hemoglobinuria (PNH) and their treating hematologists. The relationship between the ‘blood hemolytic system’ and the coagulation system was described more than six decades ago by Crosby and Dameshek.² These pioneers in the field of hematology and especially in PNH research demonstrate not only the fascination for this disease but in particular its relationship with the hemostasis system.

PNH is a condition in which uncontrolled complement activity leads to systemic complications principally through intravascular hemolysis and platelet activation. It arises through a somatic mutation of the *phosphatidylinositol glycan A (PIG-A)* gene in bone marrow stem cells³⁻⁵ resulting in disruption to glycosylphosphatidylinositol (GPI) biosynthesis⁶ and thereby a deficiency of all GPI-anchored proteins on the cell membrane.⁷⁻⁹ Among the deficient proteins are the complement regulatory proteins CD55 and CD59 resulting in increased complement sensitivity of PNH cells, intravascular hemolysis, promotion of inflammatory mediators and systemic hemoglobin release.¹⁰

Complement activation is recognized as a major contributor to vascular inflammation as well as playing a role in ischemia/reperfusion injury.¹¹ There is a real integration between the coagulation and complement systems with many complexities (reviewed in Delvaeye and Conway¹²).

Incidence and sites of thrombosis

Thromboembolism is the most common cause of mortality in patients with PNH and accounts for approximately 40% to 67% of deaths where the cause is known. Further, 29% to 44% of patients with PNH have been reported to suffer from at least one thromboembolic event in the course of their disease, although why a thrombotic event may suddenly occur remains an enigma.¹³⁻¹⁹ Analysis of data from pooled incidence cases found that in 19% of patients, visceral (hepatic, mesenteric, portal, splenic,

inferior vena cava) thrombosis preceded the diagnosis of PNH. For the remaining patients, visceral thrombosis occurred at a median of 5 years (0-24) after diagnosis.²⁰

Poor survival is associated with the occurrence of thromboembolic complications (relative risk at 8 years: 10.2).^{19, 21, 22} Patients with thrombosis at presentation have only a 40% survival rate at 4 years.¹⁹ The relative risk of death is increased 5 to 15.4-fold.¹⁷

This rate of thrombosis in PNH is likely to be underestimated, as a study using sensitive imaging techniques detected abnormalities suggestive of previous subclinical pulmonary thromboses in six of 10 patients with PNH (with no known prior thrombosis), even in patients with apparent recent disease onset. There was also evidence of subclinical myocardial damage in two of 10 patients. These subclinical thromboses are able to lead to long-term organ damage as reflected by compromised cardiac function in the majority of these patients.²³

The risk of thrombosis is greater in patients from Europe and the United States than in patients from the Far East.^{17, 18} There also appears to be an increased risk of thrombosis in African-American or Latin-American patients.¹³ The theory that patients from different ethnic groups may have additional inherited prothrombotic traits was refuted by a study demonstrating no correlation between known inherited thrombophilias and thrombosis in PNH.²⁴ However, Dragoni and colleagues have found a high rate of anti-phospholipid antibodies in patients with PNH compared with healthy volunteers and patients with aplastic anemia and gone so far as to say it could be a contributory factor to thrombosis in PNH.²⁵

While studies have reported a strong correlation between a larger PNH neutrophil clone and the occurrence of thrombosis,^{14, 16, 26} thrombosis appears to also be markedly elevated in patients with smaller clones, as low as 10%, when compared to the normal population.²⁶⁻²⁸ Additionally, Hugel and colleagues found no correlation between circulating platelet microparticles (see below) and level of PNH clone expression²⁹ partly explaining the unpredictability of thromboses seen in this condition.

Thrombosis in PNH may occur at any site. Common sites include the intra-abdominal and cerebral veins, for reasons still unknown, making thrombosis a leading cause of morbidity as well as mortality. An explanation for the propensity of intra-abdominal thrombosis in PNH is still needed. One theory proposed that as activated neutrophils lodge more readily in liver microvessels,³⁰ the CD59-negative neutrophils found in PNH are more likely to localize here, interact with platelets (which are also more readily activated) and release serine proteases, hence, concentrating procoagulant activity in this region.

Multiple sites are involved in more than a fifth of cases. Hepatic vein thrombosis (Budd-Chiari syndrome) is recognized as one of the commonest site of thrombosis and affects 7.5-25% of patients with PNH^{28, 31, 32} and may lead to hepatic failure and thereby a common cause of mortality in PNH.³³ The presentation may be with acute or chronic abdominal pain but silent thrombosis is also seen. Interestingly, of patients with Budd-Chiari syndrome, the frequency of splanchnic vein thrombosis at presentation is significantly higher in patients with PNH (47%) as compared to the non-PNH patients (10%).²⁸ Spontaneous Budd-Chiari syndrome should lead to a search for an underlying cause with the recommendation that all cases should be considered for PNH screening.²⁸

Superior sagittal sinus thrombosis (Figure 1) is the most frequent neurological complication and results in death in more than one third of cases.³⁴ There is also a greater tendency for hemorrhagic infarction following this complication. Thromboses in the sagittal sinus, lateral sinus, cavernous sinus and sigmoid sinus may all result in neurological symptoms and signs such as severe headache, vomiting, seizures, altered level of consciousness, papilloedema, VI and VII cranial nerve palsies, central retinal vein thrombosis and cerebellar or lower cranial nerve signs for sigmoid sinus thrombosis.³⁵ As the mortality rate from cerebrovascular events remains high, prompt diagnosis (frequently requiring sophisticated imaging techniques such as MRI, MRA or MRV) and a high clinical suspicion is required. Magnetic resonance imaging techniques are preferred as contrast agents with classic angiography could provoke exacerbation of hemolysis or nephrotoxicity.

Painful discolored skin lesions result when dermal veins are affected. These lesions rarely ulcerate but a separate condition resembling purpura fulminans can develop in PNH affecting larger areas of skin with necrosis (Figure 2).³⁶ Infarction of the bowel is also seen with symptoms and signs of intestinal obstruction. Mesenteric vein thrombosis results in pain which may be disproportionately exaggerated relative to the physical examination.²⁰ Thrombosis may affect the small peripheral mesenteric veins and induce transient ischemia. As well as abdominal pain there may be associated fever, obstruction and rectal bleeding. Duodenal venous thrombosis is associated with papillary endothelial hyperplasia, ulceration and a circumferential mass in the third portion of the duodenum.³⁵ The authors have observed that patients have had small bowel resections secondary to stricture formation which is likely to be ischemic in nature. Renal vein or artery thrombosis is uncommon but may result in a further cause of renal impairment in these patients.

Deep vein thrombosis of the lower limbs occurs more frequently than in the general population and has been reported in approximately one third of patients.^{15, 37} Thromboses in the pulmonary vasculature are also recognized but not always in the form of emboli or in the presence of lower limb deep vein thromboses. *In situ* formation is likely and underappreciated.

Arterial thrombosis was also the first manifestation of PNH in approximately half the reports of stroke associated with PNH.^{38, 39} It is important to recognize that arterial thromboses are also increased in patients with PNH^{26, 38, 40-43} frequently involving the cerebral and coronary arteries and supported by a recent analysis.^{44, 45}

Thrombosis is a well recognized serious complication in pregnant patients with PNH. The management in this setting will not be covered in this manuscript.

When should we test for PNH in patients presenting with thrombosis?

Unlike the finding of most inherited thrombophilias, the finding of PNH in a patient presenting with thrombosis is likely to change specific management. It is therefore suggested PNH testing is considered when investigating for thrombophilia.

Recommendations would be to consider testing for PNH by flow cytometry in those patients with unexplained thrombosis and:

1. are young
2. have a thrombosis in an unusual site e.g. intra-abdominal veins, cerebral veins, dermal veins
3. have evidence of hemolysis
4. have any cytopenia

A frequent question is whether a normal LDH could exclude PNH and therefore negate the need for sending a sample for peripheral blood flow cytometric testing. There are, admittedly rare, situations in which the LDH may not be raised such as those with a predominant Type II (partially deficient of GPI-linked proteins) red cell population in which hemolysis may be minimal, in patients who are heavily red cell transfusion dependent and in some instances where the thrombosis has occurred in a patient with a small percentage of PNH cells. Screening by flow cytometry should therefore still be considered.

Proposed mechanisms of thrombosis in PNH

This is a complex area and one of continued research interest. There is an intrinsic relationship between the coagulation cascade and the complement system that is revealed by understanding some of the mechanisms thought to result in thrombosis in PNH. Platelet activation, complement-mediated hemolysis, impaired nitric oxide (NO) bioavailability, impairment of the fibrinolytic system and inflammatory mediators are all proposed mechanisms and thought to be responsible for the increased thrombotic risk in patients with PNH. Multiple factors are likely to contribute to any one thrombotic event.

Activation of platelets

Platelet activation, known to initiate blood clotting, is likely to be the main culprit of the high incidence of thrombosis associated with PNH.^{21, 46, 47} Many mechanisms may result in platelet activation in patients with PNH. Although there is absence of CD55 on PNH platelets, platelets are capable of compensating for this with factor H present

within alpha granules.⁴⁸ The absence of CD59, however, renders platelets susceptible to attack by complement with complement-mediated activation ensuing. Although complement activation of platelets theoretically may result in lysis or removal of platelets and thereby contributes, to a minor degree, to some of the thrombocytopenia^{49, 50} the survival of platelets from PNH patients has been found to be normal.^{51, 52} The phosphatidylserine externalization and production of microparticles is recognized in cells undergoing apoptosis. Phosphatidylserine becomes a determinant for phagocyte recognition of senescent or apoptotic cells to be cleared and may contribute to lowering of the platelet count.⁵³⁻⁵⁵ This has been further supported recently when studying the effect of the complement inhibitor, eculizumab. One study found that the platelet count rose⁵⁶ while another did not.⁵⁷ The explanation for the latter study may lie in increased deposition of C3 on platelets, similar to that seen on PNH red cells for patients treated with eculizumab^{58, 59}, and increased reticuloendothelial clearance in some patients. Therefore, rather than causing lysis of platelets, the complement attack of platelets results in morphological changes and the release of vesiculated membrane attack complex. Platelet lysis is therefore minimized by this release from the cell surface of excess membrane attack complex (MAC) by exovesiculation.^{29, 48} The deposition of C5b-9 therefore leads to an increase of expression of activation dependent proteins and platelet stimulation is accompanied by the loss of membrane phospholipid asymmetry.^{47, 60, 61} These platelet vesicles or microparticles are very procoagulant *in vitro* and are present at significantly elevated levels in the blood of patients with PNH. The externalized phosphatidylserine on the microvesicles acts as a binding site for prothrombinase⁶² and tenase complexes.⁶³ Therefore, absence of CD59 from platelets probably leads to thrombin generation, an increased sensitivity to aggregation by thrombin and increased thrombotic risk, both venous and arterial.^{29, 47, 64, 65} The lack of correlation between thrombotic risk and platelet microparticles may be in part due to the fact that platelet-derived microparticles also have anticoagulant activities inhibiting fibrin formation or some platelet activation possibly due to the presence of proteins C and S in the surface of the microvesicles downregulating the prothrombinase complexes and activated factor Va.²¹

Activated platelets also interact with neutrophils and can promote thrombus formation by release of neutrophil serine proteases and nucleosomes, synergistically activating

Factor X further therefore triggering blood coagulation primarily through the extrinsic pathway.⁶⁶ This mechanism may be more prevalent in PNH due to the readily activatable state of platelets. It also remains to be explored whether PNH neutrophils more readily release serine proteases and the interaction with Tissue Factor Pathway Inhibitor (TFPI) that is already thought to be altered in PNH (see below).

The activation of platelets may also in itself perpetuate or exacerbate events, in a feedback loop, in patients through continuing the activation of the alternative pathway of complement (through P-selectin) but also by initiating activation of the classical pathway of complement due to platelet-derived chondroitin sulfate.⁶⁷⁻⁶⁹

As well as the loss of CD59, further mechanisms by which platelets are activated in PNH (Table 1) are through the depletion of NO, the direct toxicity of cell-free hemoglobin, increased reactive oxygen species causing oxidative stress, the generation of thrombin which itself further activates platelets and as a consequence of endothelial dysfunction. It should be mentioned that one study determined the platelets in PNH were hyporeactive and concluded that this may be due to chronic hyperstimulation due to continual complement system attack.⁷⁰ These findings need further research in particular to assess whether they were simply due to thrombocytopenia.

Although the complement activation of platelets does not appear to cause significant thrombocytopenia, it is well recognized clinically that an unexpected drop in a patient's platelet count may be an indicator that a thrombosis is occurring (silently in some cases) and requires further investigation. Lower resting platelet counts can be a consequence of either overt, subclinical and/or silent thromboses, hypersplenism consequent to a previous Budd-Chiari syndrome and/or liver disease and increased sensitivity of megakaryocyte progenitors in PNH to complement⁷¹. Therefore, bone marrow failure should not be considered the only reason for thrombocytopenia in patients with PNH.

Intravascular hemolysis: depletion of nitric oxide, toxicity of free hemoglobin and red cell microvesicles

Thrombotic events have been temporally associated with increased hemolysis^{16, 26, 39, 72} and intravascular hemolysis is also likely to be one of the principle contributors to thromboembolism in this disorder.^{73, 74} The multiple mechanisms by which intravascular hemolysis may contribute to thrombosis are summarized in Table 2.

Hemolysis, through factors such as toxicity of the free hemoglobin and NO depletion, has been implicated in the initiation of platelet activation and aggregation.⁷⁵ The role of free hemoglobin has been demonstrated by the infusion of cross-linked hemoglobin in rats which increases platelet aggregation and adhesion *in vivo* on prothrombotic surfaces such as an injured vessel wall.⁷⁶ Further, administration of heme in healthy volunteers causes thrombophlebitis, demonstrating that heme can cause vascular inflammation followed by vascular obstruction *in vivo*.⁷⁷ Interestingly, the addition of cell-free hemoglobin to human serum causes inhibition of the metalloprotease ADAMTS13, an enzyme critical in limiting platelet thrombus formation.⁷⁸ The effects of free hemoglobin on endothelial function are discussed below. Further disintegration of heme releases toxic species of iron which participate in biochemical reactions, such as the Fenton reaction, that generate free radicals and thus catalyze the formation of reactive oxygen species and result in loss of membrane lipid organization.⁷⁹ Phosphatidylserine positive red cells are more likely to adhere to endothelium as well as provide scaffolding for the tenase and prothrombinase complexes. Reactive oxygen species were higher and reduced glutathione lower when studied in patients with PNH and the PNH cells themselves were at higher oxidative stress.⁸⁰

NO, a free radical, binds avidly to soluble guanylate cyclase resulting in increased intracellular cyclic guanosine monophosphate (cGMP)⁸¹ (Figure 3). Cyclic GMP activates cGMP-dependent kinases that decrease intracellular calcium concentration in smooth muscle, producing relaxation, vasodilatation, and increased regional blood flow, primarily by suppressing platelet aggregation, expression of cell adhesion molecules on endothelial cells, and secretion of procoagulant proteins.^{75, 82-84} NO also limits platelet aggregation and ischemia-reperfusion injury,⁸⁵ modulates endothelial

proliferation,⁸⁶ and has anti-inflammatory properties.⁸⁷ Conversely, NO depletion is associated with platelet activation and an increase in soluble P-selectin expression,^{88, 89} which in itself can further activate the complement system.⁶⁷

NO also interacts with components of the coagulation cascade to down-regulate clot formation. For example, NO has been shown to chemically modify and inhibit Factor XIII, which suggests that NO deficiency would enhance clot stability and reduce clot dissolution.⁹⁰ Further, reduction of NO causes increases in fibrin split products and thrombin-anti-thrombin complexes leading to significant fibrin deposition and thrombus formation in an animal model.⁹¹ Reduced NO production in L-arginine deficiency has been associated with increased thrombin-anti-thrombin complexes and fibrin split products, while reversal of NO deficiency with L-arginine causes a reduction in intravascular coagulopathy.⁹²

The reaction of NO with oxyhemoglobin is fast and irreversible.⁹³ Intravascular hemolysis results in the release of free hemoglobin into the plasma. The chronic nature of the hemolysis in PNH is such that even at baseline, in between paroxysms, there is sufficient release of free hemoglobin to saturate biochemical systems in place to remove it, resulting in NO depletion. The rate of NO depletion correlates with the severity of intravascular hemolysis of which LDH is a sensitive marker.⁹⁴

In addition to hemoglobin decompartmentalization and NO scavenging, intravascular hemolysis also releases erythrocyte arginase, an enzyme that converts L-arginine, the substrate for NO synthesis, to ornithine, thereby further reducing the systemic availability of NO⁹⁵ (Figure 3).

Additionally, hemolytic rate (reticulocytosis) is associated with hemoglobin desaturation (ventilation/ perfusion mismatch) and adhesion molecule expression (intracellular adhesion molecule 1 (ICAM-1), vascular cell adhesion molecule 1 (VCAM-1) and E-selectin⁹⁶; it is possible that such a hypoxic state can induce hypoxia-inducing factor-1 (HIF-1) dependent factors such as erythropoietin, vascular endothelial growth factor (VEGF), and endothelin-1.^{73, 97} Elevated VCAM-1 correlates strongly with the presence and extent of thrombosis.⁴³

Circulating procoagulant microvesicles in association with red blood cells have also been described⁹⁸, although other investigators have found this source to be very low.^{21, 29, 99, 100} The dissemination of prothrombotic seats could therefore occur due to the presence of high levels of these procoagulant microparticles, stemming from lysed red cells (also externalizing phosphatidylserine) in the blood flow.²⁹

Deficiency or absence of other GPI-linked (or associated) proteins: urokinase-type plasminogen activator receptor (uPAR), heparan sulfate, tissue factor pathway inhibitor (TFPI) and proteinase-3

Urokinase-type plasminogen activator receptor (u-PAR; CD87) is a GPI-bound protein that is therefore absent from PNH monocytes and granulocytes. It binds pro-urokinase (uPA) to the cell surface, which converts plasminogen to plasmin and results in clot lysis. It is possible that the absence of u-PAR from the cell surface in PNH¹⁰¹ results in an increased tendency to thrombosis due to impaired fibrinolysis and reduced clot dissolution. Due to lack of anchorage of uPAR to the cell membrane, the increased plasma levels are thought to also contribute to the increased risk of venous thrombosis by competing with membrane-bound uPAR.^{102, 103} Sloand *et al.* have proposed that the combination of reduced cell-bound u-PAR with increased levels of soluble u-PAR and the presence of red cell microvesicles is a contributory factor for thrombosis in patients with PNH.¹⁰⁴ Other studies have not identified any fibrinolytic defects.²¹ Additionally, although clot dissolution may be reduced by this mechanism, could this actually result in clot initiation? It may potentiate thrombosis but is unlikely to be a sole cause of thrombosis. Fibrinolytic defects, such as plasminogen deficiency, are not generally associated with thrombosis.¹⁰⁵

Binding of antithrombin to endothelial cells is thought to be mediated by heparan sulfate, also a GPI-linked protein.¹⁰⁶ It is reduced by inflammatory markers such as IL-1 and tumor necrosis factor. Its deficiency may partly contribute to the hypercoagulable state in PNH although there have been no studies exploring this. Heparan sulfate-deficient mice have, however, been found to have the same amount of fibrin deposition as wild-type mice,¹⁰⁷ raising the possibility that there is

compensation for reduction in heparan sulfate by other glycosaminoglycans. Only complete deficiency appears to lead to thrombosis.¹⁰⁶

Tissue Factor Pathway Inhibitor (TFPI) is predominantly released by the endothelium (but is also present on the surface of monocytes, within platelets and circulating in the plasma) and is anchored, most likely indirectly, through the GPI anchor. It is a potent anticoagulant protein that abrogates blood coagulation by inhibiting both factors Xa and the tissue factor-factor VIIa catalytic complex making it the only physiologically active inhibitor of the initiation of blood coagulation. It has been suggested that defective expression or reduced activity (as TFPI is downregulated by inflammatory cytokines), potentially co-existent problems in PNH, may contribute to both arterial and venous thrombosis.^{108, 109} However, TFPI is also found within platelets and presumably expression through this route should be unaffected in patients with PNH and is an area for further study. Expression of TFPI on the surface of platelets following dual-agonist activation has been described.¹⁰⁹ This raises the question whether there is similar expression after complement activation in patients with PNH to counterbalance the reduced expression and downregulation.

Although proteinase-3 (PR3) is not itself a GPI-linked protein, it co-localizes with CD177 (NB1) which is a GPI-anchored protein. Deficiency of membrane bound PR3 on granulocytes is therefore found in PNH. Membrane bound PR3 modulates thrombus formation by cleaving the thrombin receptor and thereby decreasing thrombin-mediated platelet activation.¹¹⁰ The extent of platelet activation through this mechanism needs further study in PNH.

Endothelial dysfunction

Endothelial dysfunction occurs during any thrombotic event. Tissue factor, a key initiator of coagulation, is expressed in sub-endothelial mural cells and adventitial fibroblasts in and around the vessel wall and closely links the coagulation and complement cascades. The endothelium has also been implicated in the pathogenesis of thrombosis in hemolytic states.^{42, 43} Free hemoglobin directly impairs endothelial function. Free hemoglobin and its breakdown oxidative product heme can directly activate endothelial cells and further promote inflammation and coagulation as well as

increase tissue factor production and release of high molecular weight von Willebrand factor (vWF).

Microparticles circulating in PNH express endothelial markers: ICAM-1 (CD54), sVCAM-1, von Willebrand factor (vWF), CD144 (VE-cadherin) and CD105 (endoglin), indicating chronic endothelial activation. CD144, similarly to CD105, is derived from a sub-portion of endothelial cell junctions. It has a very short half-life in the circulation; its presence in the circulation in PNH is therefore indicative of persistent endothelial damage associated with the chronic hemolysis of PNH. A similar association has been described in sickle cell disease.^{111, 112}

As well as direct complement activation, similarly to platelets, the endothelial expression of cell adhesion molecules is also promoted by NO depletion since NO is known to suppress their expression.

Whether endothelial cells are affected by the *PIG-A* mutation is of considerable research interest. If they are found to be deficient of the complement regulatory proteins, CD55 and CD59, their dysfunction in PNH would be both primary and secondary contributors to thrombosis.

Other complement-mediated procoagulant mechanisms (independent of hemolysis)

Complement activation plays a major role in vascular inflammation. C5a may result in pro-inflammatory and pro-thrombotic processes through the generation of inflammatory cytokines such as IL-6, IL-8 and tumor necrosis factor-alpha. These will further activate the endothelium with the production of endothelial cell microparticles potentially self-perpetuating the problem. IL-6 promotes thrombin formation. Complement activation on the surface of monocytes and neutrophils is also followed by the formation of the membrane attack complex (MAC). On these cells the MAC induces cell activation and also proliferation.¹¹³ Both the MAC formation and C5a may induce the expression of tissue factor as well as plasminogen activator inhibitor 1 (PAI1) by these leukocytes. One study demonstrated that complement activation (by antiphospholipid antibodies) and downstream signaling via C5a receptors in neutrophils leads to the induction of tissue factor (Figure 3).¹¹⁴ IL-6 may

additionally deregulate the immune system and inhibit ADAMTS-13 or vWF cleaving protease activity.¹¹⁵

Much of Protein S, the cofactor for activated Protein C, circulates in complex with the complement protein C4b-binding protein, inhibiting its anticoagulant function. Decreased levels of both Proteins C and S have been found in both sickle cell disease and β -thalassemia and partly attributed to chronic consumption because of increased tissue factor expression, thrombin generation and/or hepatic dysfunction.⁷⁹ As these contributing factors are readily seen in PNH they may also be implicated in thrombosis in PNH. Patients with sickle cell disease also appear more resistant to activated protein C which may be due to increased factor VIII coagulant activity as well as the reduced protein S. Patients with PNH may again be at risk as factor VIII levels (along with vWF) are raised due to the endothelial activation.

Thrombosis in PNH is also seen at the time of infection and may be partly due to the increased hemolysis that usually coincides. There are also likely contributing hemolysis-independent mechanisms. The invading pathogens (or damaged host cells) are recognized by antigen-presenting cells, neutrophils, monocytes, macrophages, endothelial cells and platelets resulting in tissue factor exposure that is sustained by cytokines and chemokines. The pathogen can also further induce complement activation promoting generation of more C5a and MAC. C5a feeds back to promote expression of tissue factor.¹²

Finally, the pathway turns full circle with the knowledge that a fourth pathway (separate to the classical, lectin and alternative) has been described to activate the complement system in which thrombin itself cleaves and activates C3 and C5 (independent of C3).¹¹⁶ Therefore, thrombosis activates complement perhaps leading to further thrombosis in PNH and then a vicious circle ensues. This might explain the observation that once a patient has their first thrombosis this often heralds further thrombotic complications spiraling out of control despite anticoagulation until the patient eventually succumbs.

Management of thrombosis in PNH

Acute treatment of thrombosis

Thrombosis in a patient with PNH is a requirement for urgent intervention due to the high likelihood of fatality or significant disability and the rapid deterioration that frequently occurs. Attention needs to be given to the balance between bleeding (for example, due to the underlying bone marrow failure) and the highly thrombotic tendencies. Randomized controlled trials are lacking but experience has been gained in large PNH centers. The optimal management of acute thrombotic events requires immediate full anticoagulation (in the absence of major contraindications) beginning with heparin therapy (aiming for anti-Xa levels between 0.5-1.0 for those treated with low molecular weight heparin (LMWH)) and the commencement of the monoclonal antibody therapy, eculizumab. Continuing anticoagulation with the Vitamin K antagonists is generally recommended in the long-term if there are no contraindications (see secondary prophylaxis below). Recurrent thromboses and extension of existing thromboses are frequent complications in PNH. There is no published experience of the newer oral anticoagulants in PNH.

It has been reported that hemolysis may be exacerbated on the initiation of heparin as at low doses it activates the alternative complement pathway. However, at higher concentrations it acts as an inhibitor.¹¹⁷ Nevertheless, the procoagulant alteration of the PNH red cells and platelets remain.¹¹⁸ The increasing use of eculizumab during the management of acute thrombosis in patients with PNH is proving effective and our group, as well as others, has had positive experience in this setting in a number of cases including acute Budd-Chiari syndrome.¹¹⁹ In addition, the propagation of thrombosis or the occurrence of further discrete thromboses in PNH after the initial clot appears to be prevented by eculizumab. Indeed, development of any thrombosis in a patient with PNH is now considered one of the primary indications to commence eculizumab therapy and this should be done without delay. Eculizumab also halts the multiple sequential and/or simultaneous thromboses that are observed in PNH patients.

The management of Budd-Chiari syndrome in a patient with PNH, which may occur despite anticoagulant prophylaxis, is usually complex. As with other thrombotic events in this condition, immediate commencement of eculizumab is recommended. We have shown by our own series of patients in Leeds, that urgent commencement of eculizumab can reduce mortality and long-term sequelae of Budd-Chiari syndrome.¹¹⁹ Anticoagulation alone would not be expected to restore hepatic blood flow. In a series of patients with Budd-Chiari syndrome, either extension of the thrombosis or a new thrombotic event occurred in 27% despite treatment with anticoagulation.²⁸ Historically, there are reports on the use of thrombolytic therapy in this setting but this is less likely to be required with commencement of eculizumab therapy, particularly as hemorrhagic complications remain a concern. When portal hypertension is the predominant problem a TIPSS (transjugular intrahepatic portosystemic shunt) procedure is often helpful by decreasing portal pressure gradients, improving synthetic function, reducing transaminase levels and controlling ascites.¹²⁰ The main complication of TIPSS is the risk of the shunt thrombosing but in our practice this is prevented with the combination of anticoagulation and eculizumab.

Allogeneic bone marrow transplant has been previously considered but, despite improvements in other indications, the associated morbidities and mortalities in hemolytic PNH remain unsatisfactory. Liver transplantation is contraindicated due to the risk of recurrent thrombosis found in all cases of patient with PNH who had Budd-Chiari syndrome and underwent liver transplantation although most of the data are in the pre-eculizumab era.³³ There is an increased risk of the development of hepatocellular carcinoma after a Budd-Chiari syndrome and patients should be monitored for this complication, such as with regular blood tests for alfa-fetoprotein and/or liver ultrasound scans.

The previous high mortality from mesenteric vein thrombosis appeared to be associated with surgical intervention. Medical management, which would now include commencing eculizumab therapy if available, should be feasible when imaging demonstrates the bowel infarction has not led to transmural necrosis and bowel perforation.¹²¹

Prevention of thrombosis

Preventing thrombosis in PNH is an important aim in the management of patients with PNH and would be expected to lead to reduced morbidity and mortality. In vitro, heparin and low-molecular-weight heparin have been shown to inhibit the hemolysis in PNH.^{117, 118} This is probably primarily due to potentiation of C1 inhibitor¹²² but may also be due to inhibition of both the classic and alternative pathway of C3 convertases as well as interference with the assembly of the C5b-9 complex.^{123, 124} Complement activation on PNH red blood cells induces procoagulant alteration of the red cell membranes⁹⁸ but inhibition of complement-mediated lysis of PNH red cells by heparin and low-molecular-weight heparin did not result in the inhibition of complement-induced procoagulant alteration of PNH red cells.¹¹⁸ This suggests the principle mechanism of heparin action in this setting is through the interaction with C5b-9 and not through the potentiation of C1 inhibitor. There have been reports of an increased incidence of heparin-induced thrombocytopenia and consequent thrombosis¹²⁵⁻¹²⁷, thought to be explained by the increased platelet activation in PNH with induced release of platelet factor 4. If there is concern, theoretically fondaparinux may be a safer formulation.

In patients who are not treated with eculizumab, consideration of primary prophylaxis should be given to reduce the risk of thrombosis if there is no contraindication, such as thrombocytopenia or other bleeding risk.²⁶ However, there is a risk that anticoagulation in these patients may lead to complications and major hemorrhage.^{15, 16, 26, 29} The risk of hemorrhage in patients with PNH may actually be higher due to the underlying bone marrow failure which allows the PNH clone to expand. Given that eculizumab improves the management of established thrombosis in PNH then the pros and cons of prophylactic anticoagulation needs discussion with the patient. In addition, thrombocytopenia is a relative contraindication to anticoagulation and this complication is not uncommon in patients with PNH. Additionally, there are still clear cases of thromboses occurring while patients are therapeutically anticoagulated^{14, 28, 33, 37, 39, 127, 128} which is less surprising when the proposed mechanisms are considered. Following a thrombotic event it appears that anticoagulation alone as secondary prevention is not sufficient.^{127, 129}

There are no studies of anti-platelet drugs, such as aspirin or clopidogrel, in PNH but again, mechanistically, it is clear that they are unlikely to be of benefit and again there is a true risk of hemorrhage.

Considering that the mechanisms of thrombosis in PNH appear to lie with the role of platelet activation through direct complement activation as well as intravascular hemolysis and the release of free hemoglobin with all its consequent effects and mechanisms mediated through C5a, it might be anticipated that complement blockade should eliminate the risk of thrombosis although there is no prospective trial data. Therefore, in order to explore the effect of long-term treatment with eculizumab on thrombosis risk more formally, the prespecified clinical outcome of thromboembolism on an intention-to-treat basis in a multinational phase III open-label extension study that enrolled patients from 3 independent eculizumab PNH clinical studies¹³⁰⁻¹³³ (n = 195) was evaluated. Eculizumab treatment resulted in a reduction in the thromboembolism event rate in each of the individual clinical studies ($P < 0.001$).³⁷

Data for patients treated by the National PNH Centre, Leeds, UK have recently been published supporting a continuing dramatic reduction in thrombosis rate and perhaps one of the important factors behind the significantly improved initial survival for patients treated with eculizumab.⁵⁷ Further support from two studies found that eculizumab treatment of patients with PNH resulted in a rapid decrease in plasma tissue factor microparticles, thrombin generation and inflammation as measured by D-Dimers, thrombin-antithrombin complexes, plasmin-antiplasmin complexes, interleukin-6 and markers of endothelial cell activation (tissue-plasminogen activator, soluble vascular cell adhesion molecule, von Willebrand factor, and tissue factor pathway inhibitor).^{112, 134} Therefore the clinical data and the supportive mechanistic evidence indicates that eculizumab has a major impact on the management of thrombosis in PNH.

An important question, still to be addressed, is whether anticoagulation can safely be discontinued in patients with PNH who have had a previous thrombosis and are receiving eculizumab. This has been achieved successfully and reported in three patients, although longer follow-up is required.¹²⁹ Two findings support continuing anticoagulation after thrombosis: 1) the significantly lower levels of prothrombin

fragment 1+2 (a direct marker of prothrombin activation to thrombin) when anticoagulated and the reduction in soluble uPAR which only occurs when concomitantly anticoagulated^{112, 135} and 2) the report from one study demonstrating that the externalization of anionic phospholipids resulting in the procoagulant alteration of red cell membranes upon complement activation seems to occur before the step of C5b-7 insertion into the red cell membranes because C5-deficient serum also induced procoagulant alteration of PNH red cells.¹¹⁸ It seems prudent to advise continued anticoagulation in patients with a prior thrombosis who are receiving eculizumab unless there are clear contra-indications to anticoagulation or until more evidence of the safety of stopping anticoagulation is generated. Data collected from the Global PNH Registry will hopefully also aid the answer and hematologists are strongly encouraged to enroll all PNH patients, regardless of clone size or therapy, into this Registry (www.pnhregistry.org).

Conclusion

Thrombosis has been well recognized as the leading cause of death in PNH. Preventing thrombosis in this disease and effectively treating thrombosis early on in its presentation are paramount. Appreciating the high frequency of thrombosis in PNH should lead one to thorough, and possibly multiple, investigations to exclude thrombosis. A patient presenting with thrombosis should be screened for PNH if falling in one of the 4 categories described.

The tendency towards thrombosis in patients with PNH is multifactorial in etiology, involving the absence of GPI-anchored complement inhibitors on the surfaces of circulating platelets, the high levels of intravascular free plasma hemoglobin with the consequent scavenging of nitric oxide, fibrinolytic defects and the pro-inflammatory effects of C5a. The relative importance of each factor is not yet known but the integration between the 2 major host protection systems, coagulation and innate immunity, is obvious. The majority of the mechanisms relate to complement dysfunction and its consequences. Therefore eculizumab, which addresses these mechanisms resulting in the reduction of thrombosis risk, has now become an important part of the management of this most feared complication. Since thrombosis

is the leading cause of death the impact of eculizumab on thrombosis largely explains the improved survival seen with eculizumab therapy.

Authorship Contributions

AH, RK and PH all contributed to writing the review manuscript and discussions regarding the conclusions of the manuscript.

Conflict of Interest Disclosure Statement

Conflict of Interest Disclosure: Honoraria (AH, RK, PH), membership of advisory board (AH, RK, PH) and research funding (PH) - Alexion Pharmaceuticals, Inc.

Reference List

- (1) Luzzatto L, Gianfaldoni G, Notaro R. Management of paroxysmal nocturnal haemoglobinuria: a personal view. *Br J Haematol* 2011 June;153(6):709-20.
- (2) Crosby WH, Dameshek W. Paroxysmal nocturnal hemoglobinuria; the mechanism of hemolysis and its relation to the coagulation mechanism. *Blood* 1950 September;5(9):822-42.
- (3) Hillmen P, Hows JM, Luzzatto L. Two distinct patterns of glycosylphosphatidylinositol (GPI) linked protein deficiency in the red cells of patients with paroxysmal nocturnal haemoglobinuria. *Br J Haematol* 1992 March;80(3):399-405.
- (4) Nakakuma H, Nagakura S, Horikawa K et al. Interleukin-2-dependent T-cell lines established from paroxysmal nocturnal hemoglobinuria patients. *Blood* 1994 July 1;84(1):309-14.
- (5) Schubert J, Uciechowski P, Delany P, Tischler HJ, Kolanus W, Schmidt RE. The PIG-anchoring defect in NK lymphocytes of PNH patients. *Blood* 1990 September 15;76(6):1181-7.
- (6) Takeda J, Miyata T, Kawagoe K et al. Deficiency of the GPI anchor caused by a somatic mutation of the PIG-A gene in paroxysmal nocturnal hemoglobinuria. *Cell* 1993 May 21;73(4):703-11.
- (7) Armstrong C, Schubert J, Ueda E et al. Affected paroxysmal nocturnal hemoglobinuria T lymphocytes harbor a common defect in assembly of N-acetyl-D-glucosamine inositol phospholipid corresponding to that in class A Thy-1- murine lymphoma mutants. *J Biol Chem* 1992 December 15;267(35):25347-51.
- (8) Hillmen P, Bessler M, Mason PJ, Watkins WM, Luzzatto L. Specific defect in N-acetylglucosamine incorporation in the biosynthesis of the glycosylphosphatidylinositol anchor in cloned cell lines from patients with paroxysmal nocturnal hemoglobinuria. *Proc Natl Acad Sci U S A* 1993 June 1;90(11):5272-6.
- (9) Takahashi M, Takeda J, Hirose S et al. Deficient biosynthesis of N-acetylglucosaminyl-phosphatidylinositol, the first intermediate of glycosyl phosphatidylinositol anchor biosynthesis, in cell lines established from patients with paroxysmal nocturnal hemoglobinuria. *J Exp Med* 1993 February 1;177(2):517-21.
- (10) Holguin MH, Fredrick LR, Bernshaw NJ, Wilcox LA, Parker CJ. Isolation and characterization of a membrane protein from normal human erythrocytes that inhibits reactive lysis of the erythrocytes of paroxysmal nocturnal hemoglobinuria. *J Clin Invest* 1989 July;84(1):7-17.

- (11) Peerschke EI, Yin W, Ghebrehiwet B. Complement activation on platelets: implications for vascular inflammation and thrombosis. *Mol Immunol* 2010 August;47(13):2170-5.
- (12) Delvaeye M, Conway EM. Coagulation and innate immune responses: can we view them separately? *Blood* 2009 September 17;114(12):2367-74.
- (13) Araten DJ, Thaler HT, Luzzatto L. High incidence of thrombosis in African-American and Latin-American patients with Paroxysmal Nocturnal Haemoglobinuria. *Thromb Haemost* 2005 January;93(1):88-91.
- (14) de Latour RP, Mary JY, Salanoubat C et al. Paroxysmal nocturnal hemoglobinuria: natural history of disease subcategories. *Blood* 2008 October 15;112(8):3099-106.
- (15) Hillmen P, Lewis SM, Bessler M, Luzzatto L, Dacie JV. Natural history of paroxysmal nocturnal hemoglobinuria. *N Engl J Med* 1995 November 9;333(19):1253-8.
- (16) Moyo VM, Mukhina GL, Garrett ES, Brodsky RA. Natural history of paroxysmal nocturnal haemoglobinuria using modern diagnostic assays. *Br J Haematol* 2004 July;126(1):133-8.
- (17) Nishimura J, Kanakura Y, Ware RE et al. Clinical course and flow cytometric analysis of paroxysmal nocturnal hemoglobinuria in the United States and Japan. *Medicine (Baltimore)* 2004 May;83(3):193-207.
- (18) Parker C, Omine M, Richards S et al. Diagnosis and management of paroxysmal nocturnal hemoglobinuria. *Blood* 2005 December 1;106(12):3699-709.
- (19) Socie G, Mary JY, de Gramont A et al. Paroxysmal nocturnal haemoglobinuria: long-term follow-up and prognostic factors. French Society of Haematology. *Lancet* 1996 August 31;348(9027):573-7.
- (20) Poulou LS, Xila V, Rokas GI, Karianakis G, Bartzoudis D, Ziakas PD. Temporal trends in mortality rates from visceral vein thrombosis in paroxysmal nocturnal haemoglobinuria: An optimistic view. *Thromb Haemost* 2008 March;99(3):642-5.
- (21) Gralnick HR, Vail M, McKeown LP et al. Activated platelets in paroxysmal nocturnal haemoglobinuria. *Br J Haematol* 1995 November;91(3):697-702.
- (22) Ray JG, Burows RF, Ginsberg JS, Burrows EA. Paroxysmal nocturnal hemoglobinuria and the risk of venous thrombosis: review and recommendations for management of the pregnant and nonpregnant patient. *Haemostasis* 2000 May;30(3):103-17.
- (23) Hill A, Sapsford RJ, Scally A et al. Under-recognized complications in patients with paroxysmal nocturnal haemoglobinuria: raised pulmonary pressure and reduced right ventricular function. *Br J Haematol* 2012 August;158(3):409-14.

- (24) Nafa K, Bessler M, Mason P et al. Factor V Leiden mutation investigated by amplification created restriction enzyme site (ACRES) in PNH patients with and without thrombosis. *Haematologica* 1996 November;81(6):540-2.
- (25) Dragoni F, Iori AP, Pignoloni P et al. Thrombophilic screening in patients with paroxysmal nocturnal haemoglobinuria: a pilot study. *Br J Haematol* 2010 August;150(4):492-4.
- (26) Hall C, Richards S, Hillmen P. Primary prophylaxis with warfarin prevents thrombosis in paroxysmal nocturnal hemoglobinuria (PNH). *Blood* 2003 November 15;102(10):3587-91.
- (27) Fowkes FJ, Price JF, Fowkes FG. Incidence of diagnosed deep vein thrombosis in the general population: systematic review. *Eur J Vasc Endovasc Surg* 2003 January;25(1):1-5.
- (28) Hoekstra J, Leebeek FW, Plessier A et al. Paroxysmal nocturnal hemoglobinuria in Budd-Chiari syndrome: findings from a cohort study. *J Hepatol* 2009 October;51(4):696-706.
- (29) Hugel B, Socie G, Vu T et al. Elevated levels of circulating procoagulant microparticles in patients with paroxysmal nocturnal hemoglobinuria and aplastic anemia. *Blood* 1999 May 15;93(10):3451-6.
- (30) Welbourn CR, Young Y. Endotoxin, septic shock and acute lung injury: neutrophils, macrophages and inflammatory mediators. *Br J Surg* 1992 October;79(10):998-1003.
- (31) McMullin MF, Hillmen P, Jackson J, Ganly P, Luzzatto L. Tissue plasminogen activator for hepatic vein thrombosis in paroxysmal nocturnal haemoglobinuria. *J Intern Med* 1994 January;235(1):85-9.
- (32) Ziakas PD, Poulou LS, Rokas GI, Bartzoudis D, Voulgarelis M. Thrombosis in paroxysmal nocturnal hemoglobinuria: sites, risks, outcome. An overview. *J Thromb Haemost* 2007 March;5(3):642-5.
- (33) Singer AL, Locke JE, Stewart ZA et al. Successful liver transplantation for Budd-Chiari syndrome in a patient with paroxysmal nocturnal hemoglobinuria treated with the anti-complement antibody eculizumab. *Liver Transpl* 2009 May;15(5):540-3.
- (34) Poulou LS, Vakrinou G, Pomoni A et al. Stroke in paroxysmal nocturnal haemoglobinuria: patterns of disease and outcome. *Thromb Haemost* 2007 September;98(3):699-701.
- (35) Ziakas PD, Poulou LS, Pomoni A. Thrombosis in paroxysmal nocturnal hemoglobinuria at a glance: a clinical review. *Curr Vasc Pharmacol* 2008 October;6(4):347-53.
- (36) Watt SG, Winhoven S, Hay CR, Lucas GS. Purpura fulminans in paroxysmal nocturnal haemoglobinuria. *Br J Haematol* 2007 May;137(4):271.

- (37) Hillmen P, Muus P, Duhrsen U et al. Effect of the complement inhibitor eculizumab on thromboembolism in patients with paroxysmal nocturnal hemoglobinuria. *Blood* 2007 August 16;4123-8.
- (38) Abou AS, El-Haddad B, Wehbe E, Schulz T. Lysis and thrombosis: manifestation of the same disease. *Am J Hematol* 2008 June;83(6):505-7.
- (39) Audebert HJ, Planck J, Eisenburg M, Schrezenmeier H, Haberl RL. Cerebral ischemic infarction in paroxysmal nocturnal hemoglobinuria report of 2 cases and updated review of 7 previously published patients. *J Neurol* 2005 November;252(11):1379-86.
- (40) Granata G, Izzo T, Di MP et al. Thromboembolic events and haematological diseases: a case of stroke as clinical onset of a paroxysmal nocturnal haemoglobinuria. *Thromb J* 2004 November 11;2(1):10.
- (41) Hillmen P., Muus P., Dührsen U. et al. The Terminal Complement Inhibitor Eculizumab Reduces Thrombosis in Patients with Paroxysmal Nocturnal Hemoglobinuria. *Blood* 108[11], 40a-41a. 2006.
Ref Type: Abstract
- (42) Koshkaryev A, Barshtein G, Nyska A et al. 2-Butoxyethanol enhances the adherence of red blood cells. *Arch Toxicol* 2003 August;77(8):465-9.
- (43) Nyska A, Moomaw CR, Ezov N et al. Ocular expression of vascular cell adhesion molecule (VCAM-1) in 2-butoxyethanol-induced hemolysis and thrombosis in female rats. *Exp Toxicol Pathol* 2003 November;55(4):231-6.
- (44) von Stuckrad-Barre S, Berkefeld J, Steckel D, Sitzer M. Cerebral arterial thrombosis in paroxysmal nocturnal hemoglobinuria. *J Neurol* 2003 June;250(6):756-7.
- (45) Hill A, Kelly RJ, Kulasekararaj AG et al. Eculizumab in Paroxysmal Nocturnal Hemoglobinuria (PNH): A Report of All 153 Patients Treated in the UK. *Blood* 120[21], 3472. 20-11-2012.
Ref Type: Abstract
- (46) Muller F, Mutch NJ, Schenk WA et al. Platelet polyphosphates are proinflammatory and procoagulant mediators in vivo. *Cell* 2009 December 11;139(6):1143-56.
- (47) Wiedmer T, Hall SE, Ortel TL, Kane WH, Rosse WF, Sims PJ. Complement-induced vesiculation and exposure of membrane prothrombinase sites in platelets of paroxysmal nocturnal hemoglobinuria. *Blood* 1993 August 15;82(4):1192-6.
- (48) Rosse WF. *Paroxysmal nocturnal hemoglobinuria*. Hoffman, Churchill Livingstone; 2000.
- (49) Peerschke EI, Andemariam B, Yin W, Bussel JB. Complement activation on platelets correlates with a decrease in circulating immature platelets in

patients with immune thrombocytopenic purpura. *Br J Haematol* 2010 February;148(4):638-45.

- (50) Ruiz-Delgado GJ, Vazquez-Garza E, Mendez-Ramirez N, Gomez-Almaguer D. Abnormalities in the expression of CD55 and CD59 surface molecules on peripheral blood cells are not specific to paroxysmal nocturnal hemoglobinuria. *Hematology* 2009 February;14(1):33-7.
- (51) Devine DV, Siegel RS, Rosse WF. Interactions of the platelets in paroxysmal nocturnal hemoglobinuria with complement. Relationship to defects in the regulation of complement and to platelet survival in vivo. *J Clin Invest* 1987 January;79(1):131-7.
- (52) Dixon RH, Rosse WF. Mechanism of complement-mediated activation of human blood platelets in vitro: comparison of normal and paroxysmal nocturnal hemoglobinuria platelets. *J Clin Invest* 1977 February;59(2):360-8.
- (53) Allen TM, Williamson P, Schlegel RA. Phosphatidylserine as a determinant of reticuloendothelial recognition of liposome models of the erythrocyte surface. *Proc Natl Acad Sci U S A* 1988 November;85(21):8067-71.
- (54) Fadok VA, Voelker DR, Campbell PA, Cohen JJ, Bratton DL, Henson PM. Exposure of phosphatidylserine on the surface of apoptotic lymphocytes triggers specific recognition and removal by macrophages. *J Immunol* 1992 April 1;148(7):2207-16.
- (55) Martin SJ, Reutelingsperger CP, McGahon AJ et al. Early redistribution of plasma membrane phosphatidylserine is a general feature of apoptosis regardless of the initiating stimulus: inhibition by overexpression of Bcl-2 and Abl. *J Exp Med* 1995 November 1;182(5):1545-56.
- (56) Socie G, Muus P., Schrezenmeier H. et al. Terminal Complement Inhibitor Eculizumab Improves Complement-Mediated Platelet Consumption and Thrombocytopenia in Patients with Paroxysmal Nocturnal Hemoglobinuria (PNH). *Blood* 114, 4030. 2009.
Ref Type: Abstract
- (57) Kelly RJ, Hill A, Arnold LM et al. Long term treatment with eculizumab in paroxysmal nocturnal hemoglobinuria: sustained efficacy and improved survival. *Blood* 2011 April 1.
- (58) Hill A, Rother RP, Arnold L et al. Eculizumab prevents intravascular hemolysis in patients with paroxysmal nocturnal hemoglobinuria and unmasks low-level extravascular hemolysis occurring through C3 opsonization. *Haematologica* 2010 February 9.
- (59) Risitano AM, Notaro R, Marando L et al. Complement fraction 3 binding on erythrocytes as additional mechanism of disease in paroxysmal nocturnal hemoglobinuria patients treated by eculizumab. *Blood* 2009 April 23;113(17):4094-100.

- (60) Shattil SJ, Cunningham M, Wiedmer T, Zhao J, Sims PJ, Brass LF. Regulation of glycoprotein IIb-IIIa receptor function studied with platelets permeabilized by the pore-forming complement proteins C5b-9. *J Biol Chem* 1992 September 15;267(26):18424-31.
- (61) Wiedmer T, Esmon CT, Sims PJ. Complement proteins C5b-9 stimulate procoagulant activity through platelet prothrombinase. *Blood* 1986 October;68(4):875-80.
- (62) Sims PJ, Faioni EM, Wiedmer T, Shattil SJ. Complement proteins C5b-9 cause release of membrane vesicles from the platelet surface that are enriched in the membrane receptor for coagulation factor Va and express prothrombinase activity. *J Biol Chem* 1988 December 5;263(34):18205-12.
- (63) Gilbert GE, Sims PJ, Wiedmer T, Furie B, Furie BC, Shattil SJ. Platelet-derived microparticles express high affinity receptors for factor VIII. *J Biol Chem* 1991 September 15;266(26):17261-8.
- (64) Rosse WF. New insights into paroxysmal nocturnal hemoglobinuria. *Curr Opin Hematol* 2001 March;8(2):61-7.
- (65) Peerschke EI, Yin W, Alpert DR, Roubey RA, Salmon JE, Ghebrehwet B. Serum complement activation on heterologous platelets is associated with arterial thrombosis in patients with systemic lupus erythematosus and antiphospholipid antibodies. *Lupus* 2009 May;18(6):530-8.
- (66) Massberg S, Grahl L, von Bruehl ML et al. Reciprocal coupling of coagulation and innate immunity via neutrophil serine proteases. *Nat Med* 2010 August;16(8):887-96.
- (67) Del C, I, Cruz MA, Zhang H, Lopez JA, fshar-Kharghan V. Platelet activation leads to activation and propagation of the complement system. *J Exp Med* 2005 March 21;201(6):871-9.
- (68) Hamad OA, Ekdahl KN, Nilsson PH et al. Complement activation triggered by chondroitin sulfate released by thrombin receptor-activated platelets. *J Thromb Haemost* 2008 August;6(8):1413-21.
- (69) Peerschke EI, Yin W, Grigg SE, Ghebrehwet B. Blood platelets activate the classical pathway of human complement. *J Thromb Haemost* 2006 September;4(9):2035-42.
- (70) Grunewald M, Grunewald A, Schmid A et al. The platelet function defect of paroxysmal nocturnal haemoglobinuria. *Platelets* 2004 May;15(3):145-54.
- (71) Dessypris EN, Gleaton JH, Clark DA. Increased sensitivity to complement of megakaryocyte progenitors in paroxysmal nocturnal haemoglobinuria. *Br J Haematol* 1988 July;69(3):305-9.
- (72) Luzzatto L, Gianfaldoni G. Recent advances in biological and clinical aspects of paroxysmal nocturnal hemoglobinuria. *Int J Hematol* 2006 August;84(2):104-12.

- (73) Lewis DA, Nyska A, Potti A et al. Hemostatic activation in a chemically induced rat model of severe hemolysis and thrombosis. *Thromb Res* 2006;118(6):747-53.
- (74) Nyska A, Maronpot RR, Long PH et al. Disseminated thrombosis and bone infarction in female rats following inhalation exposure to 2-butoxyethanol. *Toxicol Pathol* 1999 May;27(3):287-94.
- (75) Rother RP, Bell L, Hillmen P, Gladwin MT. The clinical sequelae of intravascular hemolysis and extracellular plasma hemoglobin: a novel mechanism of human disease. *JAMA* 2005 April 6;293(13):1653-62.
- (76) Olsen SB, Tang DB, Jackson MR, Gomez ER, Ayala B, Alving BM. Enhancement of platelet deposition by cross-linked hemoglobin in a rat carotid endarterectomy model. *Circulation* 1996 January 15;93(2):327-32.
- (77) Simionatto CS, Cabal R, Jones RL, Galbraith RA. Thrombophlebitis and disturbed hemostasis following administration of intravenous hematin in normal volunteers. *Am J Med* 1988 October;85(4):538-40.
- (78) Studt JD, Hovinga JA, Antoine G et al. Fatal congenital thrombotic thrombocytopenic purpura with apparent ADAMTS13 inhibitor: in vitro inhibition of ADAMTS13 activity by hemoglobin. *Blood* 2005 January 15;105(2):542-4.
- (79) Ataga KI, Cappellini MD, Rachmilewitz EA. Beta-thalassaemia and sickle cell anaemia as paradigms of hypercoagulability. *Br J Haematol* 2007 October;139(1):3-13.
- (80) Amer J, Zelig O, Fibach E. Oxidative status of red blood cells, neutrophils, and platelets in paroxysmal nocturnal hemoglobinuria. *Exp Hematol* 2008 April;36(4):369-77.
- (81) Ignarro LJ, Byrns RE, Buga GM, Wood KS. Endothelium-derived relaxing factor from pulmonary artery and vein possesses pharmacologic and chemical properties identical to those of nitric oxide radical. *Circ Res* 1987 December;61(6):866-79.
- (82) Arnold WP, Mittal CK, Katsuki S, Murad F. Nitric oxide activates guanylate cyclase and increases guanosine 3':5'-cyclic monophosphate levels in various tissue preparations. *Proc Natl Acad Sci U S A* 1977 August;74(8):3203-7.
- (83) Hebbel RP. Auto-oxidation and a membrane-associated 'Fenton reagent': a possible explanation for development of membrane lesions in sickle erythrocytes. *Clin Haematol* 1985 February;14(1):129-40.
- (84) Voetsch B, Jin RC, Loscalzo J. Nitric oxide insufficiency and atherothrombosis. *Histochem Cell Biol* 2004 October;122(4):353-67.
- (85) Kaul DK, Hebbel RP. Hypoxia/reoxygenation causes inflammatory response in transgenic sickle mice but not in normal mice. *J Clin Invest* 2000 August;106(3):411-20.

- (86) Hebbel RP, Osarogiagbon R, Kaul D. The endothelial biology of sickle cell disease: inflammation and a chronic vasculopathy. *Microcirculation* 2004 April;11(2):129-51.
- (87) Peng HB, Spiecker M, Liao JK. Inducible nitric oxide: an autoregulatory feedback inhibitor of vascular inflammation. *J Immunol* 1998 August 15;161(4):1970-6.
- (88) Hu W, Ferris SP, Tweten RK et al. Rapid conditional targeted ablation of cells expressing human CD59 in transgenic mice by intermedilysin. *Nat Med* 2008 January;14(1):98-103.
- (89) Hu W, Jin R, Zhang J et al. The critical roles of platelet activation and reduced NO bioavailability in fatal pulmonary arterial hypertension in a murine hemolysis model. *Blood* 2010 September 2;116(9):1613-22.
- (90) Catani MV, Bernassola F, Rossi A, Melino G. Inhibition of clotting factor XIII activity by nitric oxide. *Biochem Biophys Res Commun* 1998 August 10;249(1):275-8.
- (91) Shao J, Miyata T, Yamada K et al. Protective role of nitric oxide in a model of thrombotic microangiopathy in rats. *J Am Soc Nephrol* 2001 October;12(10):2088-97.
- (92) Kayanoki Y, Kawata S, Yamasaki E et al. Reduced nitric oxide production by L-arginine deficiency in lysinuric protein intolerance exacerbates intravascular coagulation. *Metabolism* 1999 September;48(9):1136-40.
- (93) Schechter AN, Gladwin MT. Hemoglobin and the paracrine and endocrine functions of nitric oxide. *N Engl J Med* 2003 April 10;348(15):1483-5.
- (94) Hill A, Rother RP, Wang X et al. Effect of eculizumab on haemolysis-associated nitric oxide depletion, dyspnoea, and measures of pulmonary hypertension in patients with paroxysmal nocturnal haemoglobinuria. *Br J Haematol* 2010 March 8;149(3):414-25.
- (95) Morris CR, Kuypers FA, Larkin S, Vichinsky EP, Styles LA. Patterns of arginine and nitric oxide in patients with sickle cell disease with vaso-occlusive crisis and acute chest syndrome. *J Pediatr Hematol Oncol* 2000 November;22(6):515-20.
- (96) Setty BN, Stuart MJ, Dampier C, Brodecki D, Allen JL. Hypoxaemia in sickle cell disease: biomarker modulation and relevance to pathophysiology. *Lancet* 2003 November 1;362(9394):1450-5.
- (97) Gladwin MT, Kato GJ. Cardiopulmonary complications of sickle cell disease: role of nitric oxide and hemolytic anemia. *Hematology Am Soc Hematol Educ Program* 2005;51-7.
- (98) Ninomiya H, Kawashima Y, Hasegawa Y, Nagasawa T. Complement-induced procoagulant alteration of red blood cell membranes with microvesicle formation in paroxysmal nocturnal haemoglobinuria (PNH):

- implication for thrombogenesis in PNH. *Br J Haematol* 1999 July;106(1):224-31.
- (99) Horikawa K, Nakakuma H, Kawaguchi T et al. Apoptosis resistance of blood cells from patients with paroxysmal nocturnal hemoglobinuria, aplastic anemia, and myelodysplastic syndrome. *Blood* 1997 October 1;90(7):2716-22.
- (100) Whitlow M, Iida K, Marshall P, Silber R, Nussenzweig V. Cells lacking glycan phosphatidylinositol-linked proteins have impaired ability to vesiculate. *Blood* 1993 January 15;81(2):510-6.
- (101) Ploug M, Plesner T, Ronne E et al. The receptor for urokinase-type plasminogen activator is deficient on peripheral blood leukocytes in patients with paroxysmal nocturnal hemoglobinuria. *Blood* 1992 March 15;79(6):1447-55.
- (102) Ninomiya H, Hasegawa Y, Nagasawa T, Abe T. Excess soluble urokinase-type plasminogen activator receptor in the plasma of patients with paroxysmal nocturnal hemoglobinuria inhibits cell-associated fibrinolytic activity. *Int J Hematol* 1997 April;65(3):285-91.
- (103) Ronne E, Pappot H, Grondahl-Hansen J et al. The receptor for urokinase plasminogen activator is present in plasma from healthy donors and elevated in patients with paroxysmal nocturnal haemoglobinuria. *Br J Haematol* 1995 March;89(3):576-81.
- (104) Sloand EM, More K, Shah S et al. Soluble Urokinase Plasminogen Activator Receptor Is Increased in Patients with Paroxysmal Nocturnal Hemoglobinuria (PNH) and Thrombosis and Inhibits Plasmin Generation In Vitro and Promotes Thrombosis in the Mouse Model. *Blood* 108. 2006. Ref Type: Abstract
- (105) Tefs K, Gueorguieva M, Klammt J et al. Molecular and clinical spectrum of type I plasminogen deficiency: A series of 50 patients. *Blood* 2006 November 1;108(9):3021-6.
- (106) Weitz JI. Heparan sulfate: antithrombotic or not? *J Clin Invest* 2003 April;111(7):952-4.
- (107) HajMohammadi S, Enjyoji K, Princivalle M et al. Normal levels of anticoagulant heparan sulfate are not essential for normal hemostasis. *J Clin Invest* 2003 April;111(7):989-99.
- (108) Maroney SA, Cunningham AC, Ferrel J et al. A GPI-anchored co-receptor for tissue factor pathway inhibitor controls its intracellular trafficking and cell surface expression. *J Thromb Haemost* 2006 May;4(5):1114-24.
- (109) Maroney SA, Mast AE. Expression of tissue factor pathway inhibitor by endothelial cells and platelets. *Transfus Apher Sci* 2008 February;38(1):9-14.

- (110) Jankowska AM, Szpurka H, Calabro M et al. Loss of expression of neutrophil proteinase-3: a factor contributing to thrombotic risk in paroxysmal nocturnal hemoglobinuria. *Haematologica* 2011 July;96(7):954-62.
- (111) Simak J, Holada K, Risitano AM, Zivny JH, Young NS, Vostal JG. Elevated circulating endothelial membrane microparticles in paroxysmal nocturnal haemoglobinuria. *Br J Haematol* 2004 June;125(6):804-13.
- (112) Helley D, Peffault de LR, Porcher R et al. Evaluation of hemostasis and endothelial function in patients with paroxysmal nocturnal hemoglobinuria receiving eculizumab. *Haematologica* 2010 January 15.
- (113) Cole DS, Morgan BP. Beyond lysis: how complement influences cell fate. *Clin Sci (Lond)* 2003 May;104(5):455-66.
- (114) Ritis K, Doumas M, Mastellos D et al. A novel C5a receptor-tissue factor cross-talk in neutrophils links innate immunity to coagulation pathways. *J Immunol* 2006 October 1;177(7):4794-802.
- (115) Mounzer K, DiNardo A, Goldstein K. Thrombotic thrombocytopenic purpura during immune reconstitution. *AIDS* 2007 November 30;21(18):2559-60.
- (116) Huber-Lang M, Sarma JV, Zetoune FS et al. Generation of C5a in the absence of C3: a new complement activation pathway. *Nat Med* 2006 June;12(6):682-7.
- (117) Logue GL. Effect of heparin on complement activation and lysis of paroxysmal nocturnal hemoglobinuria (PNH) red cells. *Blood* 1977 August;50(2):239-47.
- (118) Ninomiya H, Kawashima Y, Nagasawa T. Inhibition of complement-mediated haemolysis in paroxysmal nocturnal haemoglobinuria by heparin or low-molecular weight heparin. *Br J Haematol* 2000 June;109(4):875-81.
- (119) Haughton J, Kelly RJ, Richards S.J. et al. Improved Outcomes of Budd-Chiari Syndrome in Paroxysmal Nocturnal Hemoglobinuria with Eculizumab Therapy. *Blood* 120[21], 3478. 16-11-2012.
Ref Type: Abstract
- (120) Khuroo MS, Al-Suhayni H, Al-Sebayel M et al. Budd-Chiari syndrome: long-term effect on outcome with transjugular intrahepatic portosystemic shunt. *J Gastroenterol Hepatol* 2005 October;20(10):1494-502.
- (121) Brunaud L, Antunes L, Collinet-Adler S et al. Acute mesenteric venous thrombosis: case for nonoperative management. *J Vasc Surg* 2001 October;34(4):673-9.
- (122) Caughman GB, Boackle RJ, Vesely J. A postulated mechanism for heparin's potentiation of C1 inhibitor function. *Mol Immunol* 1982 February;19(2):287-95.

- (123) Kazatchkine MD, Fearon DT, Metcalfe DD, Rosenberg RD, Austen KF. Structural determinants of the capacity of heparin to inhibit the formation of the human amplification C3 convertase. *J Clin Invest* 1981 January;67(1):223-8.
- (124) Maillet F, Petitou M, Choay J, Kazatchkine MD. Structure-function relationships in the inhibitory effect of heparin on complement activation: independency of the anti-coagulant and anti-complementary sites on the heparin molecule. *Mol Immunol* 1988 September;25(9):917-23.
- (125) Huehn C, Righini M, Starobinski M, Angelillo-Scherrer A, de MP. Are patients with paroxysmal nocturnal hemoglobinuria at risk for heparin-induced thrombocytopenia? *J Thromb Haemost* 2003 February;1(2):389-90.
- (126) Magnan H, Kayton ML, DiMichele DM, Araten DJ, Kernan NA, Boulad F. Splenic infarction and subsequent splenic rupture in a patient with paroxysmal nocturnal hemoglobinuria and heparin-induced thrombocytopenia. *Pediatr Blood Cancer* 2009 September;53(3):472-4.
- (127) Araten DJ, Notaro R, Thaler HT et al. Thrombolytic therapy is effective in paroxysmal nocturnal hemoglobinuria: a series of 9 patients and a review of the literature. *Haematologica* 2011 December 1.
- (128) Cheng KL, Brody J, Warshall CE, Sloand EM, Allen SL. Paroxysmal nocturnal hemoglobinuria following alemtuzumab immunosuppressive therapy for myelodysplastic syndrome and complicated by recurrent life-threatening thrombosis despite anticoagulation: successful intervention with eculizumab and fondaparinux. *Leuk Res* 2010 April;34(4):e85-e87.
- (129) Emadi A, Brodsky RA. Successful discontinuation of anticoagulation following eculizumab administration in paroxysmal nocturnal hemoglobinuria. *Am J Hematol* 2009 October;84(10):699-701.
- (130) Hill A, Hillmen P, Richards SJ et al. Sustained response and long-term safety of eculizumab in paroxysmal nocturnal hemoglobinuria. *Blood* 2005 October 1;106(7):2559-65.
- (131) Hillmen P, Hall C, Marsh JC et al. Effect of eculizumab on hemolysis and transfusion requirements in patients with paroxysmal nocturnal hemoglobinuria. *N Engl J Med* 2004 February 5;350(6):552-9.
- (132) Hillmen P, Young NS, Schubert J et al. The complement inhibitor eculizumab in paroxysmal nocturnal hemoglobinuria. *N Engl J Med* 2006 September 21;355(12):1233-43.
- (133) Brodsky RA, Young NS, Antonioli E et al. Multicenter phase III study of the complement inhibitor eculizumab for the treatment of patients with paroxysmal nocturnal hemoglobinuria. *Blood* 2007 November 30.
- (134) Weitz IC, Razavi P, Rochanda L et al. Eculizumab therapy results in rapid and sustained decreases in markers of thrombin generation and inflammation

in patients with PNH independent of its effects on hemolysis and microparticle formation. *Thromb Res* 2012 September;130(3):361-8.

- (135) Kakkar VV, Hoppenstead DA, Fareed J et al. Randomized trial of different regimens of heparins and in vivo thrombin generation in acute deep vein thrombosis. *Blood* 2002 March 15;99(6):1965-70.

Table 1: Causes of activated platelets in PNH
1. Complement-mediated through loss of CD59 and assembly of C5b-9 on the surface
2. Nitric oxide depletion
3. Direct effects of free hemoglobin
4. Increased levels of reactive oxygen species
5. Endothelial dysfunction
6. Thrombin activation

Table 2: Consequences of intravascular hemolysis in the mechanisms of thrombosis in PNH

<ol style="list-style-type: none">1. Release of free hemoglobin resulting in:<ol style="list-style-type: none">a. Platelet activationb. Thrombophlebitisc. Nitric oxide (NO) depletion with consequences of:<ol style="list-style-type: none">i. Vasoconstrictionii. Platelet activation and aggregationiii. Increased expression of cellular adhesion moleculesiv. Secretion of procoagulant proteinsv. Ischemia-reperfusion injuryvi. Endothelial proliferationvii. Increased inflammatory markersviii. Factor XIII activationix. Increased levels of thrombin-antithrombin complexes and fibrin split productsd. Inhibition of ADAMTS13e. Direct endothelial dysfunctionf. Activation of endothelial cells and release of microparticlesg. Increased levels of tissue factorh. Increased levels of reactive oxygen species
2. Release of arginase - resulting in NO depletion
3. Release of pro-coagulant red cell microparticles

Table 3: Proposed hemolysis-independent mechanisms of thrombosis in PNH
1. Platelet activation through <ul style="list-style-type: none">a) direct complement activityb) reactive oxygen speciesc) endothelial dysfunctiond) thrombin activation
2. Deficiency of uPAR (although may only be significant in the presence of red cell microparticles)
3. Deficiency of heparan sulfate
4. Deficiency of TFPI
5. Deficiency of proteinase-3
6. Endothelial cell activation
7. C5a mediated mechanisms <ul style="list-style-type: none">a) Increase in inflammatory cytokinesb) Downregulation of ADAMTS-13
8. Generation of tissue factor and PAI1 from PNH monocytes and neutrophils
9. Decreased levels of Protein S
10. Protein C resistance due to increased factor VIII activity
11. Thrombin activation of the complement system perpetuating mechanisms above

Figure 1: magnetic resonance angiography in a patient with PNH and superior sagittal sinus thrombosis with collateral vessel formation

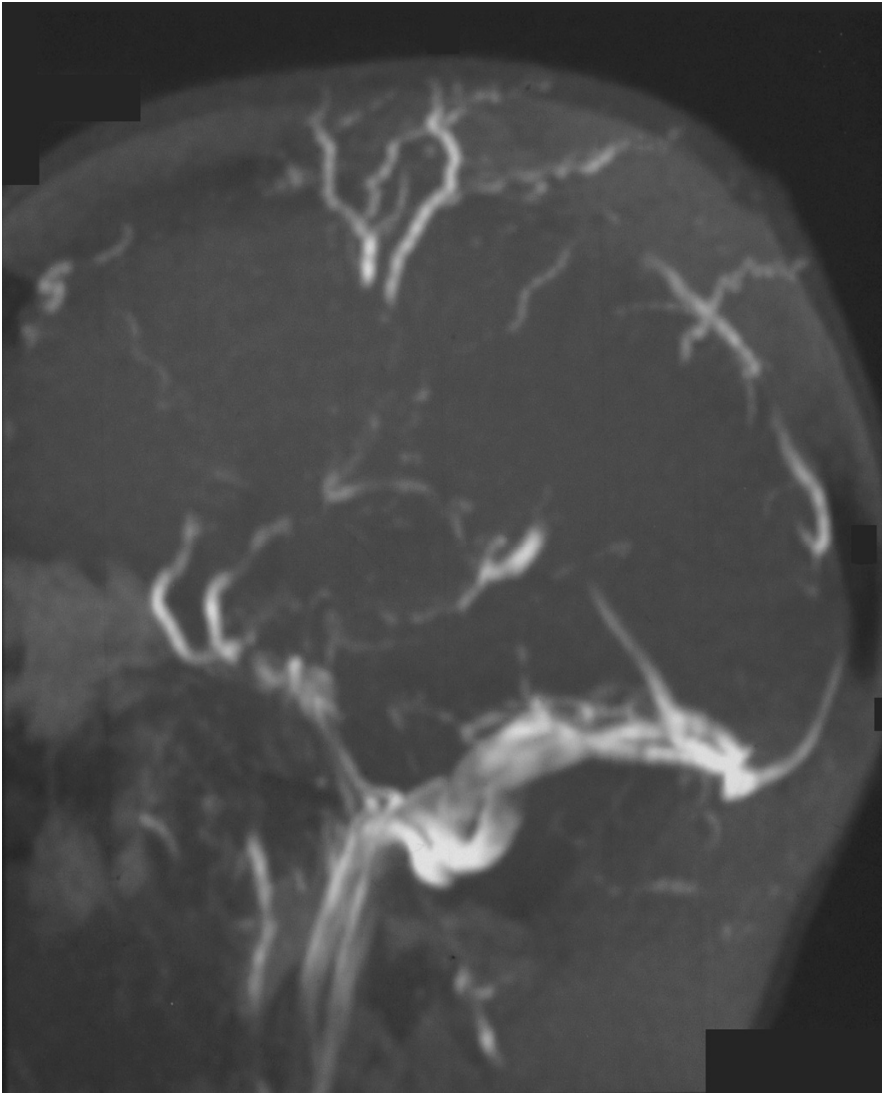
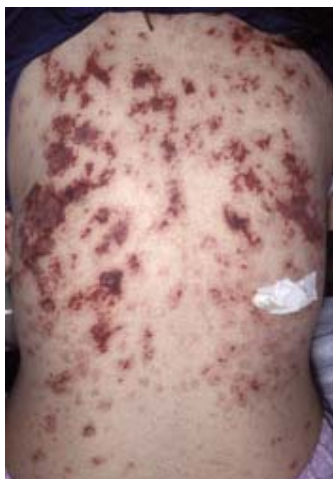

Figure 2: Case of dermal vein thromboses in a patient known to have PNH



(Reproduced with permission from Watt SG, Winhoven S, Hay CR, Lucas GS.
Purpura fulminans in paroxysmal nocturnal haemoglobinuria. *Br.J.Haematol.*
2007;137:271, publishers John Wiley & Sons Ltd.)

Figure 3: Close integration between the complement cascade (grey) and the coagulation cascade (green). The relationships with red cell hemolysis, platelet activation, endothelial cells and white blood cells are also demonstrated. Detailed information regarding each interaction is given the text.

